

EVIDENCE OF AN *OXYSPIRURA PETROWI* EPIZOOTIC IN NORTHERN BOBWHITES (*COLINUS VIRGINIANUS*), TEXAS, USA

Nicholas R. Dunham,¹ Liza A. Soliz,^{1,2} Alan M. Fedynich,² Dale Rollins,³ and Ronald J. Kendall^{1,4}

¹ The Wildlife Toxicology Laboratory, The Institute of Environmental and Human Health, Texas Tech University, Box 41163, Lubbock, Texas 79409, USA

² Caesar Kleberg Wildlife Research Institute, Texas A&M University-Kingsville, 700 University Blvd., Kingsville, Texas 78363, USA

³ Texas AgriLife Research, Texas A&M University System, San Angelo, Texas 76901, USA

⁴ Corresponding author (email: ron.kendall@ttu.edu)

ABSTRACT: We captured 36 Northern Bobwhites (*Colinus virginianus*) in Mitchell County, Texas in June–September 2013, and examined them for the eyeworm *Oxyspirura petrowi*. We recovered 334 eyeworms from 28 of 29 adult bobwhites (97%); infections ranged from 1–40 worms and mean (\pm SD) abundance of 11.9 ± 13.0 . Three of seven juveniles were infected, and those infected had one eyeworm each. Prevalence of eyeworms was similar among months. However, mean abundance of eyeworms peaked in July and August (3.3 ± 2.1 , 13.5 ± 15.0 , and 16.9 ± 15.5), and decreased in September (6.3 ± 3.0). We suggest that several previous studies may underreport prevalence and abundance because in those studies only the eye surface and nictitating membrane were examined, and not eye-associated tissue, ducts, glands, or sinuses.

Key words: *Colinus virginianus*, eyeworm, Northern Bobwhite, *Oxyspirura petrowi*, Rolling Plains Ecoregion, Texas.

INTRODUCTION

Northern Bobwhites (*Colinus virginianus*) are declining throughout their range. The causes are unclear, but many have pointed to extremes in rainfall patterns, declining quality of habitat, and habitat fragmentation (e.g., Guthery et al. 1988; Duren et al. 2011; Blank 2013). However, bobwhite populations have declined even in areas considered good-quality habitat, such as the Rolling Plains ecoregion of Texas (Rollins 2007). Historically, bobwhites thrived throughout the Rolling Plains ecoregion, producing large numbers of harvested quail. Bobwhite populations in this region now are highly variable and have continued to decline over the past two decades (Texas Parks and Wildlife Department 2013), suggesting other factors may be contributing to the decline. Often overlooked is the potential impact of parasites and diseases, despite studies in Europe documenting the role of cecal nematodes in negatively affecting various population parameters in several species of free-ranging Galliformes (e.g., Hudson 1986; Draycott et al. 2006).

The eyeworm *Oxyspirura petrowi* is a heteroxenous nematode that received recent interest in the role it may play in negatively affecting game birds (Villarreal et al. 2012). Eyeworm-infected bobwhites were found dead after flying into buildings and other man-made structures (Rolling Plains Quail Research Ranch, unpubl. data) and Jackson (1969) reported infected bobwhites behaving erratically. These reports led to speculation that eyeworms may be causing visual obstruction.

Cram (1937) reported *O. petrowi* and *O. mansoni* in several avian species from North America. However, *O. mansoni* is typically found in poultry and can result in demonstrated pathology (Ruff 1984), whereas *O. petrowi* occurs in wild avian species (Pence 1975), particularly Galliformes (e.g., McClure 1949; Landgrebe et al. 2007), including Northern Bobwhites in the Rolling Plains ecoregion (Jackson 1969; Villarreal et al. 2012). However, evidence of pathologic consequences of *O. petrowi* is lacking (Villarreal et al. 2012) and most examinations were based solely on visual inspection.

Herein we report three findings made during a larger, ongoing study known as Operation Idiopathic Decline, which is a multiyear collaborative effort to investigate parasites and diseases occurring in quail within the Rolling Plains of Texas and Oklahoma. The first is evidence of a possible eyeworm epizootic during the summer of 2013. Second is finding eyeworms in eye-associated ducts and glands and in the nasal sinuses, which has important implications for parasitologic studies with the use of data obtained exclusively from examination of the eye surface and nictitating membrane. Lastly, eyeworms were found attached to tissue and ingesting blood.

MATERIALS AND METHODS

Study area

The study was conducted on a 120,000-ha privately owned cattle ranch in Mitchell County, Texas (32°7'45"N, 100°59'6"W). Mean annual daily temperatures in this county range from 35.6 C in July to -1.1 C in January with annual precipitation of 50 cm per year (Texas A&M AgriLife Extension 2013). Dominant vegetation includes honey mesquite (*Prosopis glandulosa*), juniper (*Juniperus pinchotti*), prickly pear (*Opuntia* spp.), silver bluestem (*Bothriochloa saccharoides*), and lotebrush (*Ziziphus obtusifolia*) (Rollins 2007).

Trapping

From June to September 2013, Northern Bobwhites were trapped and handled according to Texas Parks and Wildlife permit SRP-1098-984 and consistent with Texas A&M University Acceptable Use Policy 2011-193, Texas Tech University Animal Care and Use Committee 11049-07, and Texas Tech University Animal Care and Use Committee 13027-03. Voucher specimens of *O. petrowi* (107283) were deposited in the US National Parasite Collection, Beltsville, Maryland.

Sixty welded-wire walk-in double funnel traps (91.4×60.9×20.3 cm) were placed near a minimally traveled ranch road (32°10'N, 101°55'W) at 0.4-km intervals and covered with clippings from surrounding vegetation. Traps were left open but baited weekly with milo (*Sorghum bicolor*) for 1 mo prior to trapping. During trapping sessions, traps were closed until trapping was finished. Closed traps were monitored daily at 2 hr after

sunrise and 1 hr before sunset or at sunset. After each trapping session, all traps were opened. Captured bobwhites were transported to The Institute of Environmental and Human Health (TIEHH) Aviary at Texas Tech University and held in individual 25×61-cm cages prior to examination. Bobwhites were supplied feed (Purina® Game Bird Chow; Gray Summit, Missouri, USA), water, and grit ad libitum while being held. All bobwhites were held at TIEHH for ≤3 days before being euthanized.

Eyeworm examinations

Eyeworms were extracted with the use of techniques developed during an ongoing study at TIEHH. Live bobwhites were restrained manually to reduce struggle, and two drops of a topical anesthetic (0.5% proparacaine HCl ophthalmic solution; Alcon Labs, Lake Forest, Illinois, USA) were applied directly on the eye to reduce potential discomfort. To ensure the eye was fully anesthetized, a paintbrush hair strand was laid over the eye and observed for eye immobilization or absence of reactivity. After the eye was fully anesthetized, tissue-dressing forceps (Sontec 14-4340; Sontec Instruments, Centennial, Colorado, USA), lightly lubricated in GenTeal gel (Novartis Ophthalmics, St. Louis, Missouri, USA) to provide lubrication and minimize irritation and the potential for corneal ulcerations, were used to examine the quail eye. Upper and lower eyelids were lifted gently and examined for eyeworms. The nictitating membrane was pulled gently over the eye for examination then manipulated gently up and down to initiate movement of eyeworms that were not found previously. A magnifying ocular headset (Donegan DA-5 OptiVisor headband magnifier, 2.5× magnification, 20-cm focal length; Donegan Optical, Lenexa, Kansas, USA) and a light source helped to facilitate eyeworm collection. If eyeworms were present and could not be extracted with forceps, the eye was flushed with balanced salt solution (BSS, Alcon Laboratories, Fort Worth, Texas, USA) with the use of a 22-ga. irrigation cannula. Extracted eyeworms were placed in physiologic saline solution at 37 C (Schwabe 1951).

Bobwhites were euthanized approximately 1 day after initial examination with the use of a carbon dioxide chamber (Kent Scientific Corp., Torrington, Connecticut, USA) followed by cervical dislocation. Once euthanization had taken place, the lower eyelid was lifted, reexamined, and removed with the use of scissors. The upper eyelid was lifted and reexamined and the nictitating membrane was

TABLE 1. Prevalence, abundance, and number of eyeworms (*Oxyspirura petrowi*) collected in adult Northern Bobwhites (*Colinus virginianus*) captured in Mitchell County, Texas, USA during June–September 2013.

Month	Prevalence	Abundance	Number of eyeworms
June	3 of 3	3.3±2.1	10
July	6 of 6	13.5±15.0	81
August	10 of 11	16.9±15.5	186
September	9 of 9	6.3±3.0	57

located and pulled over the eye to initiate movement of eyeworms not found previously. The eyeball was removed with the use of scissors and forceps so the orbital area, lacrimal gland and ducts, and nasal cavity could be examined for eyeworms. Excised eyeworms were placed in physiologic saline solution at 37 C. All eyeworms were visually examined with a magnifying ocular headset immediately after extraction.

It was difficult to remove some eyeworms because of their strong attachment to the tissues of the eye. When eyeworms released from the tissue and were removed, blood was seen around the point of attachment, around the mouth of the parasite, and inside the body of the parasite. This condition was witnessed multiple times over the examination process. Eyeworm blood ingestion was confirmed visually with a magnifying ocular headset and by using phase-contrast microscopy. The phase contrast allowed us to see the blood-meal contents of the intestinal tract and to confirm that eyeworms were ingesting blood.

Statistical analyses and terminology

We conducted chi-square analyses to compare the prevalence of eyeworms between host gender and host age classes. Prevalence of eyeworms was not analyzed because it was similar among all months. Because our parasite data were not normally distributed and our sample size was small, we used a standard 1,000 bootstrap method on our mean abundance data. We then performed a Welch's two-sample *t*-test on the output. Significance was inferred at $P \leq 0.05$ level.

Parasitologic terminology follows that of Bush et al. (1997). Prevalence refers to the number of bobwhites infected with *O. petrowi* in the sample divided by total bobwhites examined in the sample, and mean abundance

is the number of *O. petrowi* found in the bobwhite sample divided by the total number of bobwhites examined.

RESULTS

Presence of eyeworms

The surface of the eye, nictitating membrane, and eye-associated ducts, glands, and nasal sinus of 36 Northern Bobwhites (29 adults, 7 juveniles; 21 males and 15 females) were examined for *O. petrowi*. Of the 29 adult bobwhites, 28 were infected with 1–40 eyeworms and averaged 11.9 ± 13.0 [SD]. Prevalence was consistent among months, ranging from 91–100%, and mean abundance of eyeworms increased from June (3.3 ± 2.1), peaked in August (16.9 ± 15.5), and decreased in September (6.3 ± 3.0) (Table 1). These bobwhites were captured along the same trap-transect line throughout the duration of the study.

Three of seven juveniles were infected with one eyeworm each. Higher mean abundance of eyeworms occurred in adult males than juvenile males (12.3 ± 13.5 and 1.0 ± 1.7 , respectively; $P < 0.0001$) and in adult females than juvenile females (10.5 ± 12.6 and 1.0 ± 1.4 , respectively; $P < 0.0001$). Mean abundance of eyeworms between sexes was similar (male: 9.6 ± 12.7 , female 9.3 ± 12.2 , $P = 0.8027$). Although females appeared to have a higher prevalence of infection compared to males, the difference was not significant (93.3% vs. 80.9%, respectively; $\chi^2_1 = 1.12$, $P = 0.29$). Adult bobwhites had a significantly greater prevalence compared to juveniles (96.5% vs. 42.8%, respectively ($\chi^2_1 = 13.6$, $P < 0.0001$) (Table 2). Cumulative monthly rainfall totals increased from May and June and peaked in July, respectively, before dropping in August and September (Fig. 1).

Eyeworm recovery

The number of eyeworms collected from the eye surface and nictitating membrane of live birds during the initial examination was fewer than the number of eyeworms collected from the nasal–lacrimal–sinus

TABLE 2. Prevalence, abundance, and number of eyeworms (*Oxyspirura petrowi*) by host age and sex from Northern Bobwhites (*Colinus virginianus*) captured in Mitchell County, Texas, USA, from June–September 2013.

	Sample size	Prevalence		Abundance	No. of eyeworms
		No. quail infected	% infected		
Male					
Adults	16	15	93.8	12.3±13.5	197
Juveniles	5	2	40	1.00±1.7	5
Total	21	17	81.0	9.6±12.7	202
Female					
Adults	13	13	100	10.5±12.6	137
Juveniles	2	1	50	1.0±1.4	2
Total	15	14	93.3	9.3±12.2	139

area upon necropsy 1 day later. Additionally, live bobwhites that had eyeworms removed during the initial examination of the eye surface and nictitating membranes were found to be infected in the same locations upon examination during necropsy. In bobwhites with >10 eyeworms, a majority of the worms were found inhabiting and tightly packed into the lacrimal duct with a maximum of 30 eyeworms found in one duct. In these cases, the lacrimal duct was visually larger and inflamed with distinct petechial hemorrhaging as compared to bobwhites with no eyeworms recovered (Fig. 2).

Eyeworms varied visually in size, color, and shape, indicating the presence of both

juvenile and adult worms. It was common to find both adult and juvenile eyeworms inhabiting the same areas of the eye in the same Northern Bobwhite. Juvenile eyeworms were much shorter and thinner, and appeared transparent, whereas adult eyeworms were much longer and thicker, and more opaque in color. Female eyeworms were examined under a microscope to look for eggs. If eggs were seen they were considered gravid and adult, otherwise they were considered juveniles (Fig. 3).

DISCUSSION

Many studies reporting *O. petrowi* relied on donated, hunter-shot birds killed

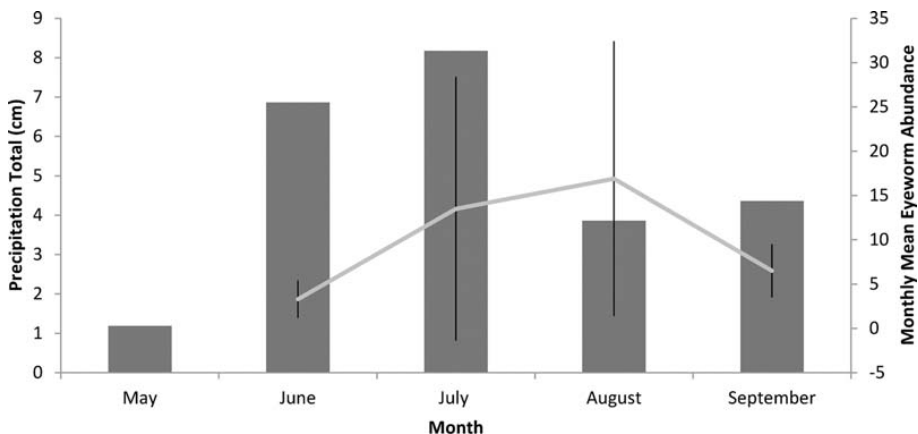


FIGURE 1. Bar graph represents monthly precipitation totals and line graph represents mean abundance ±SD of eyeworms (*Oxyspirura petrowi*) found in adult Northern Bobwhites (*Colinus virginianus*) from a study area in Mitchell County, Texas, USA, May–September 2013.

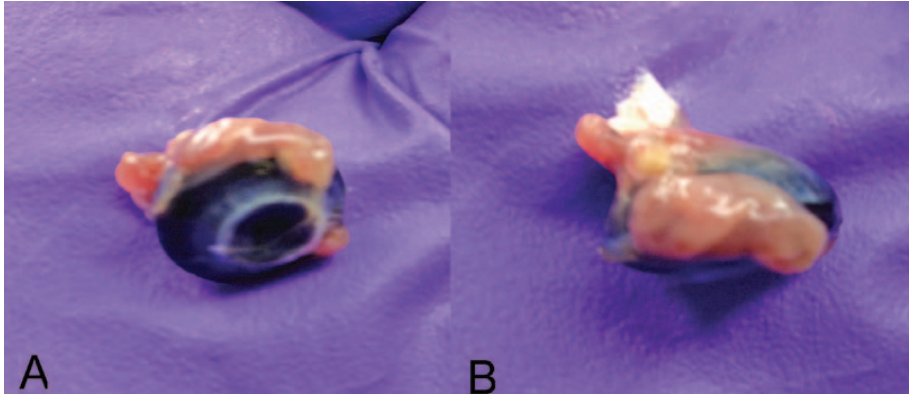


FIGURE 2. (A) Front view of an eyeball of a Northern Bobwhite (*Colinus virginianus*) captured in Mitchell County, Texas, USA, showing inflamed lacrimal duct associated with an infection of eyeworms (*Oxyspirura petrowi*). (B) Top view of the same eyeball of a bobwhite showing an inflamed lacrimal duct.

during the fall and winter (e.g., Erickson et al. 1949; Pence et al. 1980) or during periods before the breeding season (Davidson et al. 1991). Davidson et al. (1991) examined bobwhites collected in February from 1971 to 1984 in northern Florida and found only 3 bobwhites in 700 to be infected with one *Oxyspirura matogrosensis* (likely *O. petrowi*, based on Pence 1972). Because these studies with the use of hunter-shot birds are reporting “survivors” (i.e., individuals still remaining in the population to be sampled) of various

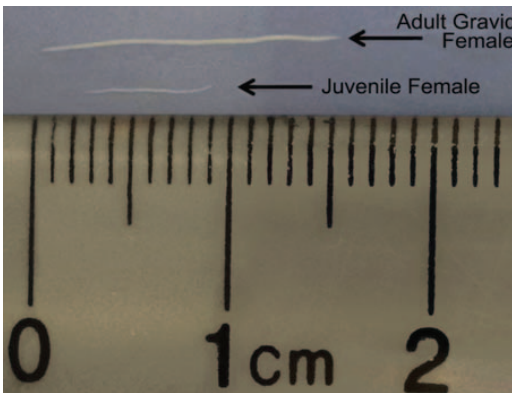


FIGURE 3. Juvenile and adult female eyeworms (*Oxyspirura petrowi*) removed from Northern Bobwhites (*Colinus virginianus*) captured in Mitchell County, Texas, USA. Maturity of the eyeworm was determined by size, color, and shape and a phase-contrast microscope was used to determine the presence or absence of eggs.

biotic and abiotic insults encountered during the breeding season, it is likely that eyeworm prevalence and abundance is underreported during the winter if eyeworms have a direct or indirect impact on bird survival. Unfortunately, little is known regarding *O. petrowi* transmission, infection, and population dynamics during summer. McClure (1949) sampled Ring-necked Pheasants (*Phasianus colchicus*) during the summer, but only averaged four eyeworms per bird with a gross infection of 40%, whereas Robel et al. (2003) recorded 95% infection with an average of 14 eyeworms per Lesser Prairie-Chicken (*Tympanuchus pallidicinctus*) sampled, which is comparable to our present study. However, it is unclear if either McClure (1949) or Robel et al. (2003) examined all the tissues where *O. petrowi* can occur in a host, as done in our study. We found high overall prevalence and increased numbers of juvenile *O. petrowi* as we continued to trap throughout the summer. During June and July, trapping was difficult because insects deterred Northern Bobwhites from foraging in our milo-baited traps. In addition, all eyeworms collected from bobwhites in June were immature but, by July, the majority of eyeworms collected were mature based on their size, and gravid females were present. These observations

seemed to occur as a result of increased rainfall on the study area from early June to September, which in turn caused an explosion of intermediate hosts. An increasing number of intermediate hosts would likely facilitate eyeworm transmission during summer, evidenced by increased *O. petrowi* abundance and different developmental stages within individual bobwhites. Villarreal (2011) examined the helminth community of 51 (juvenile, $n=29$, 6–10 wk old; adult, $n=22$) bobwhites in Fisher County, Texas (Rolling Plains ecoregion) during drought conditions of summer (August) 2010 and reported *O. petrowi* prevalence, intensity, and abundance of 33%, 4.0 ± 0.8 (SE), and 1.0 ± 0.4 , respectively. In addition, of the juveniles examined, only two were infected with three eyeworms. Those results are substantially lower than our findings. It is possible that the rainfall events on our study area triggered new vegetation growth, thereby triggering expansive population growth of intermediate hosts of *O. petrowi*, which were then exploited by foraging bobwhites. Alternatively, it is possible that wetter conditions, relieving previous drought conditions on the study area, may increase *O. petrowi* egg survival within the environment prior to ingestion by intermediate hosts. Further examination is needed to elucidate the relationship between rainfall and host infection rates.

Sanders (1928) and Schwabe (1950) reported severe pathologic effects from *O. mansoni* in domestic poultry, including inflammatory response, corneal opacity, nasal discharge, damage to the eye, and eventual blindness. However, little is known about the negative effects of *O. petrowi* on individuals or populations of bobwhites. Based on our finding of eyeworms in the nasal–lacrima–orbital tissue and observing eyeworms connected to orbital tissue ingesting blood, high numbers of *O. petrowi* can cause inflammation and localized petechiae/spot hemorrhaging to the lacrimal duct.

Several studies on *O. petrowi* are unclear in their descriptions of how birds were examined for eyeworms (e.g., Erickson et al. 1949; Villarreal et al. 2012), whereas others were clearly explained (e.g., Sanders 1928; Schwabe 1951). Such inconsistencies in the methods or reporting of methods make it difficult to determine if the results are reflective of the true infection. Inconsistent methods may also result in a substantial number of worms being missed, which could result in lower estimates of prevalence, intensity, and abundance. Insufficient examinations may result in erroneous conclusions that infections are inconsequential when they could be more consequential than previously thought.

There are many other factors that need to be looked at when determining the impact of eyeworms on Northern Bobwhites. Infection could render the host susceptible to impaired respiratory function, visual obstruction leading to an inability to find/secure food or escape predators, and increased energy expenditure. Additional studies are warranted to determine whether infections caused by *O. petrowi* could lead (directly or indirectly) to increased host susceptibility to other infections or influence predator–prey dynamics. Negative impacts of *O. petrowi* may be worse than previously believed. More in-depth investigations are needed to assess the consequences of eyeworm infections.

ACKNOWLEDGMENTS

Funding for this research was provided by the Rolling Plains Quail Research Foundation. We thank the Rolling Plains Quail Research Ranch, Sara Pappas, Brad Thomas, Adric Olson, and Galen Austin for laboratory and field assistance. We also thank Steve White and Randy Bullard for their continuous hospitality and access to our study ranch.

LITERATURE CITED

- Blank PJ. 2013. Northern bobwhite response to Conservation Reserve Program habitat and landscape attributes. *J Wildl Manage* 77:68–74.

- Bush AO, Lafferty KD, Lotz JM, Shostak AW. 1997. Parasitology meets ecology on its own terms: Margolis et al. revisited. *J Parasitol* 83:575–583.
- Cram EB. 1937. A review of the genus *Oxyspirura*, with a morphological study of *O. petrowi* Skrjabin 1929, recently discovered in galliform birds of the northern United States. In: Papers on Helminthology Published in Commemoration of the 30 Year Jubileum of K. I. Skrjabin and of the 15th Anniversary of the All-Union Institute of Helminthology. Moscow, Russia, pp. 89–98.
- Davidson WR, Kellogg FE, Doster GL, Moore CT. 1991. Ecology of helminth parasitism in bobwhites from northern Florida. *J Wildl Dis* 27:185–205.
- Draycott RAH, Woodburn MIA, Ling DE, Sage RB. 2006. The effect of an indirect anthelmintic treatment on parasites and breeding success of free-living pheasants *Phasianus colchicus*. *J Helminthol* 80:409–415.
- Duren KR, Buler JJ, Jones W, Williams CK. 2011. An improved multi-scale approach to modeling habitat occupancy of northern bobwhite. *J Wildl Manage* 75:1700–1709.
- Erickson AB, Highby PR, Carlson CE. 1949. Ruffed grouse populations in Minnesota in relation to blood and intestinal parasitism. *J Wildl Manage* 13:188–194.
- Guthery FS, Koerth NE, Smith DA. 1988. Reproduction on northern bobwhites in semiarid environments. *J Wildl Dis* 52:144–149.
- Hudson PJ. 1986. The effect of a parasitic nematode on the breeding production of red grouse. *J Anim Ecol* 55:85–92.
- Jackson AS. 1969. *Quail management handbook for west Texas Rolling Plains*. Bulletin No. 48. Texas Parks and Wildlife Department, Austin, Texas, 75 pp.
- Landgrebe JN, Vasquez B, Bradley RG, Fedynich AM, Lerich SP, Kinsella JM. 2007. Helminth community of Scaled Quail (*Callipepla squamata*) from western Texas. *J Parasitol* 93:204–208.
- McClure HE. 1949. The eyeworm, *Oxyspirura petrowi*, in Nebraska pheasants. *J Wildl Manage* 13:304–307.
- Pence DB. 1972. The genus *Oxyspirura* (Nematoda: Thelazidae) from birds in Louisiana. *Helm Soc Wash* 39:23–28.
- Pence DB. 1975. Eyeworms (Nematoda: Thelazidae) from west Texas quail. *Proc Helminthol Soc Wash* 42:181–183.
- Pence DB, Young VE, Guthery FS. 1980. Helminths of the Ring-necked Pheasant, *Phasianus colchicus* (Gmelin) (Phasianidae), from the Texas panhandle. *Proc Helminthol Soc Wash* 47:144–147.
- Robel RJ, Walker TL Jr, Hagen CA, Ridley RK, Kemp KE, Applegate RD. 2003. Helminth parasites of Lesser Prairie-chicken *Tympanuchus pallidicinctus* in southwestern Kansas: Incidence, burdens and effects. *Wildl Biol* 9:341–349.
- Rollins D. 2007. Quails on the Rolling Plains. In: *Texas quails: Ecology and management*, Brennan L, editor. Texas A&M University Press, College Station, Texas, USA, pp. 117–141.
- Ruff MD. 1984. Nematodes and acanthocephalans. In: *Diseases of poultry*, 8th Ed, Hofstad MS, Calnek BW, Helmboldt CF, Reid WM, Yoder HW Jr, editor. Iowa State University Press, Ames, Iowa, pp. 614–648.
- Sanders DA. 1928. Manson's eyeworm of poultry. *J Am Vet Assoc* 25:568–584.
- Schwabe CW. 1950. Studies on *Oxyspirura mansoni*, the tropical eyeworm of poultry III. Preliminary observations on eyeworm pathogenicity. *Am J Vet Res* 11:286–290.
- Schwabe CW. 1951. Studies on *Oxyspirura mansoni*, the tropical eyeworm of poultry. II. Life history. *Pacif Sci* 5:18–35.
- Texas A&M AgriLife Extension. 2013. *Extension education in Mitchell County*, <http://mitchell.agrilife.org/>. Accessed March 2014.
- Texas Parks and Wildlife Department. 2013. *Bobwhite and scaled quail in the Rolling Plains*, http://www.tpwd.state.tx.us/huntwild/hunt/planning/quail_forecast/forecast/rolling_plains/. Accessed March 2014.
- Villarreal SM. 2011. *Helminth infections across the annual breeding cycle of northern bobwhites from Fisher County, Texas*. MS Thesis, Texas A&M University, Kingsville, Texas, 93 pp.
- Villarreal SM, Fedynich AM, Brennan LA, Rollins D. 2012. Parasitic eyeworm *Oxyspirura petrowi* in northern bobwhites from the Rolling Plains of Texas, 2007–2011. *Proc Nat Quail Symp* 7:241–243.

Submitted for publication 21 October 2013.

Accepted 19 February 2014.